



Spinal Tuberculosis: An Unusual Presentation

KEYWORDS

DR SANDEEP INCHANALKAR

DEPARTMENT OF SURGERY; D.Y.PATIL MEDICAL COLLEGE, D.Y. PATIL UNIVERSITY, KOLHAPUR

DR AMIT GARUD

DEPARTMENT OF SURGERY; D.Y.PATIL MEDICAL COLLEGE, D.Y. PATIL UNIVERSITY, KOLHAPUR

ABSTRACT *We report a rare case of pre vertebral cold abscess of dorsal spine in a 40 yr old man, who presented with neck swelling. He had a soft swelling in the right side of neck, progressively increasing. He also had imbalance and backache. On imaging it was tuberculosis of dorsal spine with formation of cold abscess and ascending in the neck. We drained the abscess from non dependant neck incision and the spine decompression done by D3-D laminectomy. The patient responded to this with ANTI TB chemotherapy.*

INTRODUCTION

Tuberculosis of spine is seen in less than 1% of all tuberculosis cases. It leads to crippling deformities because the diagnosis often gets delayed (2). Though abscess formation is common in the lower dorsolumbar region of the spine, its formation in the cervical and upper dorsal spine is comparatively rare (0.03%) (4). We present a case of caries spine in which the cold abscess originating from dorsal spine progressed anteriorly to push the trachea to left side and presenting as neck swelling. Only a few such cases have been reported in the literature (4).

CASE REPORT

A 40 yr old, non smoker, male presented with four months history of loss of appetite and swelling in the front of neck with imbalance and backache. There was no history of cough, haemoptysis. There was no past history of TB (tuberculosis). On examination, he weighed 48 kg, swelling in the right side of neck of 6cm in size, it was soft fluctuant (Fig No-4). Neurological examination showed evidence of dorsal myelopathy, sensory level up to D2. Examination of lungs was normal. Tenderness on dorsal spine D2-D5. Investigations revealed Hb-9 G %, TLC- 4800, ESR-50 mm. Mantoux test positive, sputum AFB negative. Chest ray was normal. MRI spine showed a D4 -D5 lesion, with end plate destruction of bodies with sclerosis and formation of abscess anteriorly extending anteriorly upto C4-C5 and forming a neck swelling. It was hypointense on T2W, suggesting a liquefied abscess (Fig No-1).

We suspected tuberculosis of dorsal spine with cord compression and cold abscess in the neck. And decided to do exploration of D4-D5 and did laminectomy with cord decompression in prone position. Later turned the patient and did non dependant drainage of cold abscess, inserted an infant feeding tube and aspirated the pus it was approximately 100 cc pus (Fig No-2). Post operatively he was put on four drug AKT and was given bed rest for 3 weeks. Later he was mobilised with dorsolumbar corset, the histopathology also confirmed the diagnosis of TB. Patient also responded well, started gaining weight and improved in gait, the neck swelling also disappeared.

DISCUSSION

Commonly, patients of TB spine present in first three decades of life. Typically, the symptoms are insidious (4 months to 4 years) (6). With backache, malaise, loss of ap-

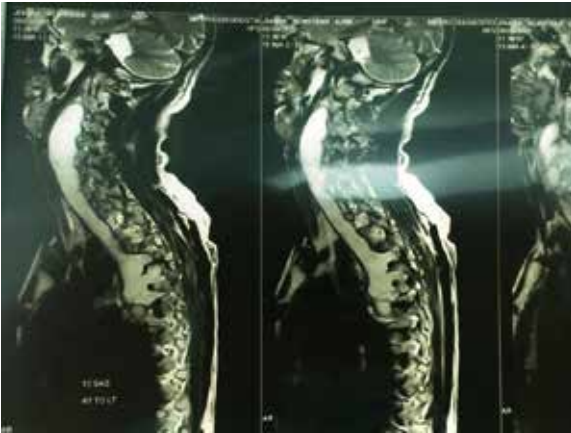
petite and weight, night sweats and evening rise of temperature. Spine is stiff and painful on movement with localized tenderness. Kyphotic deformity is seen in 95% cases (2). The deformity may not develop in the early detected and less severe cases, as in the present case. Lumbar and dorsolumbar spine is most commonly affected. Cervical and upper dorsal spine is rarely involved (3). Pre and para vertebral abscess formation is commonly seen, usually presenting far away from the vertebral column along the fascial planes or along the course of neurovascular bundles (2). It may present in the paraspinal regions at the back, in the posterior or anterior cervical triangles or along the intercostal spaces on the chest wall. Abscess from dorsolumbar and lumbar spine track down the psoas sheath (2). But an abscess arising from cervical or dorsal spine, presenting anteriorly and causing airway obstruction is very rarely seen (3, 4). Similar to our case, 2 cases of dorsal spinal TB with extra pleural extension of para vertebral abscess presenting as space occupying lesion (4). Ten to thirty percent of cases of caries spine are associated with neurological complications (2). In our case there was a neurological deficit. Spinal tuberculosis is the result of haematogenous dissemination from a primary focus. The detection of primary focus or visceral tuberculosis is reported in between 40% to 50% of cases (5). Whereas in a series reports the detection of primary focus in only upto 12% of cases (2). In our patient, no primary focus could be detected.

MRI scan is helpful in these lesions to detect and know the extent (8). Patients treated conservatively or in conjunction with radical surgical extirpation, have shown good results. Studies from Hong Kong, Korea and Rhodesia indicate that Isoniazid and PAS given for 18 months were highly effective (9). 80% of patients achieving favourable status by 3 years. No added benefit was reported from six months bed rest, or additional 3 months of streptomycin (9). The Hong Kong operation which involved resection of spinal focus and bone space grafting with anterior spinal fusion showed no added benefit over ambulatory anti tuberculosis therapy (10). Short course therapy (6-9 months) with RHZ (Z for initial 2 months) is also highly effective (10). In our case surgical debridement with cord decompression and ambulatory chemotherapy has shown fast recovery (Fig No-3). Early detection of spinal tuberculosis can help in preventing the serious complications like paraplegia and death. Careful history, examination and MRI

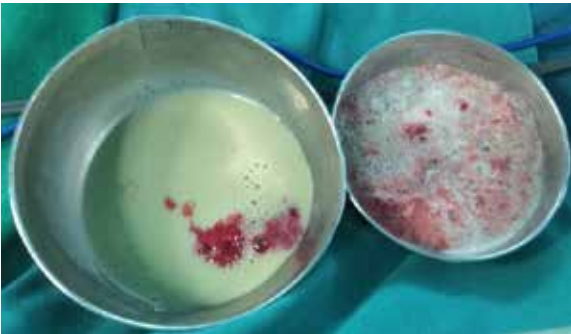scan can help even in unusual presentation.

FIGURES-

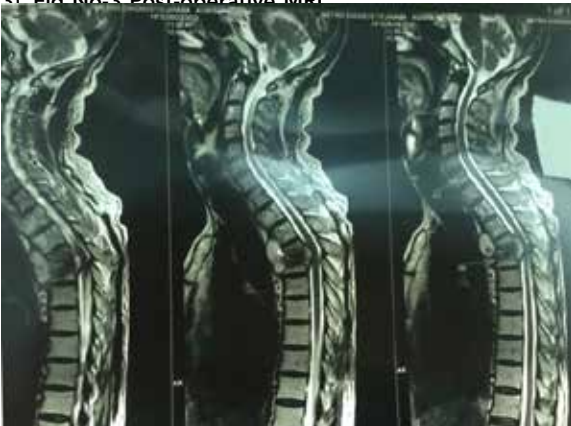1) Fig No-1 Pre-operative MRI



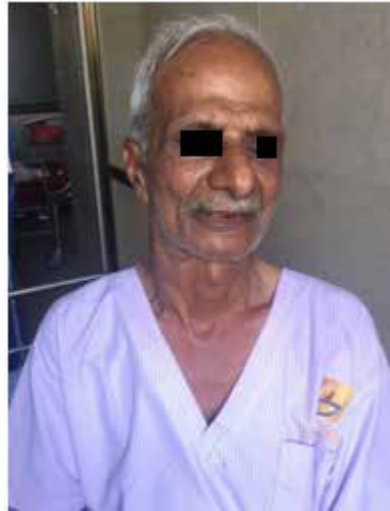2) Fig No-2 Pus drained



3) Fig No-3 Post-operative MRI



4) Fig No-4 Pre-operative clinical



REFERENCE

- Omar, B. Robertson J.M., Nelson R.J., Chiu L.C., Pott's disease. A resurgent challenge to the thoracic surgeon. *Chest* 1989 Jan.95 (1):145.
- Tuli S.M., Tuberculosis of the spine. In: Tuli S.M.ed. *Tuberculosis of the skeletal system*. J.P.Brothers, New Delhi 1991, 132,253.
- Wurtz, R. Quader Z. Simon D.Langer B. Cervical tuberculosis vertebral osteomyelitis: a case report and discussion of literature. *Clin. Infect Dis.*, 1993, June, 16 (6):806.
- Sathyamoorthy, Pott. Extension of para vertebral abscess in tuberculosis of the thoracic spine; report of two cases *Med.J.Malaya* 1990, Dec, 45 (4):329.
- Friedman, B. Chemotherapy of tuberculosis of the spine. *J.Bone Joint Surg.* 1966, 48-A: 451.
- Walker. G.F.Failure of early detection skeletal tuberculosis. *Br.Gorse, G.J. Pais, J. M., Kurske J.A., Cesario T. C.* Tuberculosis spondylitis: a report of six cases and a review of the literature. *Medicine (Baltimore)* 1983, 62:178.
- Smith, D.F., Smith F. W., Douglas J. G. Tubercular Radiculopathy, the value of magnetic resonance imaging of the neck. *Tubercle* 1989, 70:213.
- Medical research council working party on tuberculosis of the spine, 1982. A 10 year controlled trial comparing debridement and anterior spinal fusion in the management of tuberculosis of spine in patients on standard chemotherapy in Hong Kong. *J. Bone Joints Surg* 1982, 64B:393.
- Medical research council working party on tuberculosis of the spine (1986). A controlled trial of six months and nine months regimen of chemotherapy in patients undergoing radical surgery for tuberculosis of the spine in Hong Kong *tubercle* 1986, 67:243.